



PATIENT

Fred Burke

SPECIES

Canine

BREED

Pomeranian

SEX

Female Spayed

AGE

9 years

WEIGHT

10.5lbs

INTERPRETED BY

Maggie Machen Lamy,
DVM, DACVIM
(Cardiology)

IMAGING PERFORMED BY

Melissa Weisman,
DVM

HOSPITAL NAME

Minnesota Veterinary
Ultrasound

REFERRING VET

Dr. Weisman

INVOICE

45833

DATE

11/19/25

PRESENTING CLINICAL SIGNS

History: History of IMA. ALP elevated, tracheal collapse; on Cerenia 4mg EOD. CXR showed cardiomegaly with concern for PAH. Sedated with trazadone, gabapentin and butorphanol.
-CXR report: bronchitis, possible RHE, tracheal collapse.

RADIOGRAPHIC FINDINGS *NOTE: Images submitted for supplemental cardiac information only.

Possible right-sided cardiomegaly. No obvious evidence of CHF.

ECHOCARDIOGRAM FINDINGS

2D, m-mode, color flow and doppler imaging is available. Normal mitral valve leaflets with no prolapse into the left atrial lumen. Trace mitral regurgitation with no left atrial dilation. Normal LV diameter with adequate myocardial function. The tricuspid valve appears normal with trace tricuspid regurgitation. Normal velocity. Normal right atrial and ventricular diameter and morphology indicating no overt evidence of pulmonary arterial hypertension. The pulmonic and aortic valves are normal in morphology and mobility. Normal pulmonic and aortic outflow velocities with laminar flow. No obvious aortic or pulmonic insufficiency. No pericardial or pleural effusion noted. No obvious cardiac masses.

CARDIAC CHART

CANINE CARDIAC PARAMETERS	MR VMAX (m/s)	TR VMAX (m/s)	LA/AO (Boon method)	LA/AO (Heart Base; Swe)	FS (%)	EF (%)	EPSS (cm)
NORMAL PARAMETER	4.5-5.5	<2.7	1.3	<1.6	28-40	40-100	<0.6
PATIENT	NM	2.5	NM	1.3	40	74	NM
CANINE CARDIAC PARAMETERS	HR (BPM)	AV VMAX (m/s)	PV MAX (m/s)	BODY WEIGHT (kg)	LA 2D short axis Base view (cm)	LVIDd Avg; 2D and m-mode short axis (cm)	LVIDs Avg; 2D and m-mode short axis (cm)
NORMAL PARAMETER	50-100	0.7-1.7	0.7-1.6	BELOW	BELOW	BELOW	BELOW
PATIENT	130	1.0	1.0	4.8	1.7	2.1	1.3
*Normal chamber parameters expressed as a mean value (SD)				3	1.27 (5.3)	2.46 (2.46)	1.36 (5.5)
BODY WEIGHT DEPENDENT PARAMETERS				5	1.40 (4.5)	2.74 (5.2)	1.60 (4.7)
*Note: All measurements based upon multi-modal images and methods. An average value is reported.				10	1.50 (3.8)	3.27 (3.5)	2.06 (3.1)
				15	1.83 (2.0)	3.71 (2.4)	2.43 (2.1)
				20	2.02 (1.9)	4.14 (2.2)	2.80 (2.0)
				25	2.18 (2.4)	4.48 (2.9)	3.10 (2.5)
				30	2.33 (3.3)	4.83 (3.9)	3.39 (3.4)
				35	2.48 (4.3)	5.17 (5.0)	3.69 (4.5)
				40	2.62 (5.2)	5.48 (6.1)	3.96 (5.4)
				50	2.88 (7.1)	6.07 (8.3)	4.46 (7.4)

INTERPRETATION OF THE FINDINGS & FURTHER RECOMMENDATIONS

Overtly normal cardiac dimensions and function, with no obvious dysfunction or dilation of the left heart. Trace MR and TR may reflect early valve disease or may simply be physiologic in origin. Follow up is advised should a murmur develop in the future. No significant valvular leaks are visualized, and no evidence of pulmonary hypertension.



PATIENT

Fred Burke

SPECIES

Canine

BREED

Pomeranian

SEX

Female Spayed

AGE

9 years

WEIGHT

10.5lbs

INTERPRETED BY

Maggie Machen Lamy,
DVM, DACVIM
(Cardiology)

IMAGING PERFORMED BY

Melissa Weisman,
DVM

HOSPITAL NAME

Minnesota Veterinary
Ultrasound

REFERRING VET

Dr. Weisman

INVOICE

45833

DATE

11/19/25

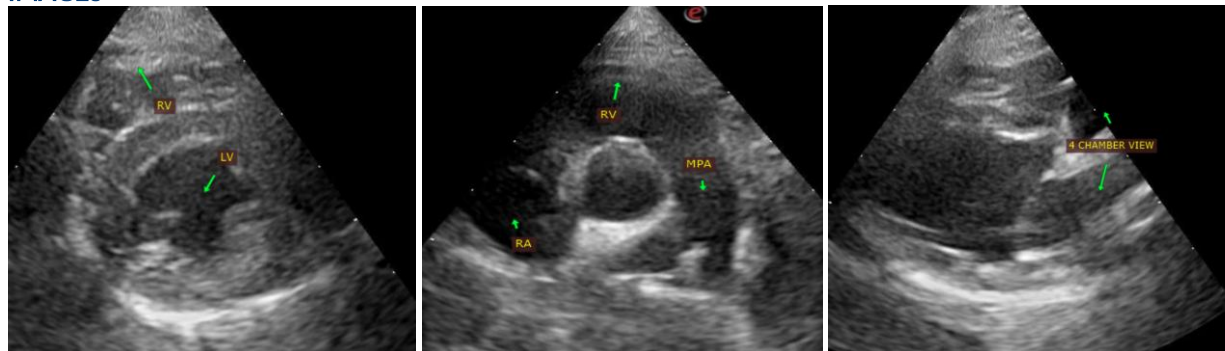
These findings would suggest the radiographic appearance is likely a normal anatomic variant. These films should be used as a baseline for future comparison.

No cardiac medications are indicated at this time as the cough is certainly non-cardiac in origin. Continued work up for infectious/inflammatory respiratory causes is recommended. Options include Baytril or similar antibiotic, anti-inflammatory prednisone, aggressive hydrocodone, etc. If refractory, may consider TTW/BAL for further information.

Monitor for development of a heart murmur, acutely progressive cough, labored breathing, exercise intolerance or collapse episodes.

Chronic respiratory issues can lead to pulmonary hypertension if poorly controlled and a recheck echocardiogram is recommended should any exertional syncope/dyspnea occur, or a murmur be noted in the future.

IMAGES



The information and recommendations provided are based on the images presented by the referring veterinarian. No evaluation can be communicated regarding pathology that was not visible in the image/video clips provided.

Thank you for this referral. This report was generated using transcription software, and minor dictation errors may be present. If the clinical or image interpretation does not parallel your findings or if I can be of any further assistance, please contact me.

Maggie Machen Lamy, DVM
Diplomate of the American College of Veterinary Internal Medicine (Cardiology)
info@sonopath.com